

## Clinical Investigation of a Novel Surgical Device for Circumcision

Yiming Yuan, Zhichao Zhang,\* Wanshou Cui, Bing Gao, Jing Peng,  
Zhongcheng Xin and Yinglu Guo

From the Andrology Center of Peking University First Hospital, Beijing, People's Republic of China

**Purpose:** We investigated the performance of a novel device for adult circumcision, that is the circular cutter with stapled anastomosis for circumcision.

**Materials and Methods:** A total of 62 men with a mean  $\pm$  SD age of  $28 \pm 8$  years were enrolled from June to September 2012 to undergo circumcision using the circular cutter with stapled anastomosis. The device used 18 staples for anastomosis, which fall out during the recovery course, as designed. Patients were followed at day 3, and weeks 1, 2, 4 and 12 after the procedure. Outcome measures were evaluated, including patient safety, procedural time, patient satisfaction and complication rate.

**Results:** Average procedural time needed to use the device was  $7.7 \pm 2.6$  minutes. Patients returned to full physical activity on postoperative day 3. The overall complication rate was 4.8%, including 1 case of intraoperative bleeding due to operator inexperience and 2 of a delay in staples falling out. No patient experienced wound infection or excessive foreskin excision. No incision site edema was observed beyond postoperative day 7. All enrolled patients were satisfied with the postoperative penile cosmesis.

**Conclusions:** The circular cutter with stapled anastomosis for circumcision is a 1-step device that can achieve excellent postoperative results with minimal procedural time. Therefore, it has the potential to enable the performance of circumcision as a rapid turnover bedside procedure.

**Key Words:** penis; circumcision, male; anastomosis, surgical; equipment and supplies; surgical staplers

CIRCUMCISION, one of the most commonly performed urological procedures, has been described since ancient Egyptian time.<sup>1</sup> Indications for circumcision range from preventing urinary tract infection to decreasing the risk of penile cancer and HIV transmission.<sup>2-4</sup> Also, many men undergo circumcision for cultural reasons, social acceptance or cosmesis. However, like any surgical procedure, circumcision carries the risk of complications, such as hemorrhage, infection, wound dehiscence, excessive

foreskin removal, urethrocutaneous fistula and glans injury.<sup>5</sup>

Most currently reported techniques can be categorized as dorsal slit, clamp, sleeve excision, and shield and sutureless techniques.<sup>6-10</sup> A number of available circumcision devices are based on these techniques, such as the Gomco® and Mogen clamps, Plastibell,<sup>8</sup> Alisklamp®,<sup>9</sup> PrePex™<sup>11</sup> and Shang Ring.<sup>12</sup> The drawbacks of these devices include possible complications, including bleeding, excessive foreskin excision

### Abbreviations and Acronyms

CCSAC = circular cutter with stapled anastomosis for circumcision

Accepted for publication November 26, 2013.  
Study received institutional research and ethics committee approval.

\* Correspondence: No. 59A, Di'anmen West St., Xicheng District, Beijing, People's Republic of China (telephone: +86-10-83228989-8288; FAX: +86-10-83222822; e-mail: [zhangzhichao@bjmu.edu.cn](mailto:zhangzhichao@bjmu.edu.cn)).

(Gomco clamp and Plastibell), asymmetrical circumcision (Mogen clamp), glans injury and separate procedures needed for ring or suture removal (PrePex, Shang Ring and Alisklamp). Using these techniques extensive care is usually required after the procedure due to postoperative pain and discomfort, prolonged healing time and surgical site edema resulting from the compression ring. Urethrocutaneous fistula was also reported after Plastibell and Gomco circumcisions.<sup>13</sup> Often these complications are a result of compression necrosis from a retained ring, incorrect bell placement, delayed suturing after incision or direct injury from incorrect clamp placement.<sup>13–15</sup> Thus, the devices must be improved to overcome these problems.<sup>5</sup>

CCSAC (Lang He®) is a new disposable circumcision device invented in 2009 that is designed to achieve the mentioned goals. It was inspired by the circular end-to-end stapling devices and end-to-end anastomosis stapler<sup>16</sup> commonly used in bowel anastomosis procedures. CCSAC is designed with a glans bell, a trigger, a circular scalpel and a built-in stapler (fig. 1). It is operated by simply squeezing its handles to trigger the circular scalpel blade and stapler, thereby removing the foreskin and creating the anastomosis at the same time. The glans bell of the CSSAC is available in 3 sizes (D26, D30 and D36) for adults and 2 sizes for pediatric patients.

CSSAC completes the steps of foreskin removal, hemostasis and anastomosis in 1 action by combining a circular scalpel blade and anastomosis staples in 1 device, allowing for a short procedural time. The staples used for suturing are 3.5 mm long and designed to fall out on between 7 and 14 days postoperatively. Since it has no postoperative ring attachment, it results in minimal postoperative

pain and edema. Health care institutions could also consider the economic advantage of performing circumcision as a rapid, low complexity bedside procedure with a novel disposable (not reusable) device that costs about \$200.

However, this novel device has not been thoroughly discussed in the literature. We investigated the performance and outcome of CSSAC in adults.


## MATERIALS AND METHODS

A total of 69 men were evaluated for CCSAC at our andrology center from June to September 2012. None required repeat circumcision. Candidates eligible for study were between 18 and 65 years old. Indications for CCSAC included a long prepuce, congenital or acquired phimosis and recurrent balanoposthitis (see table). Patients were excluded from study if they had a history of bleeding disorder, any severe allergy, uncontrolled diabetes (2) or genital anomalies such as micropenis (2), hypospadias (2), Peyronie disease (1) or significant penile curvature. As a result, 62 patients were chosen to undergo circumcision using CCSAC after receiving approval from our institutional research and ethics committee. Written informed consent forms, including privacy rules, were signed by patients for study inclusion.

Routine preprocedural blood and urine tests were performed to assess patient baseline health conditions. Patients were prepared and draped in the usual sterile fashion in a procedure room. Regional dorsal nerve anesthesia was administered using 1% lidocaine hydrochloride at the base of the penis. No sedation, preoperative antibiotic or anticoagulation was administered. Adhesions at the distal end of the penis were lysed with mosquito forceps by blunt dissection or excised with a scalpel with the patient under nerve block anesthesia. CCSAC was then used to complete circumcision. Two urologists and 1 resident performed these procedures in our department under the supervision of a urologist.

CCSAC consists of a glans bell with a column and wing nut, a strapping tape and a handler (fig. 2). The bell and handler are available in 3 sizes (D26, D30 and D36) for different sizes of adult glans.

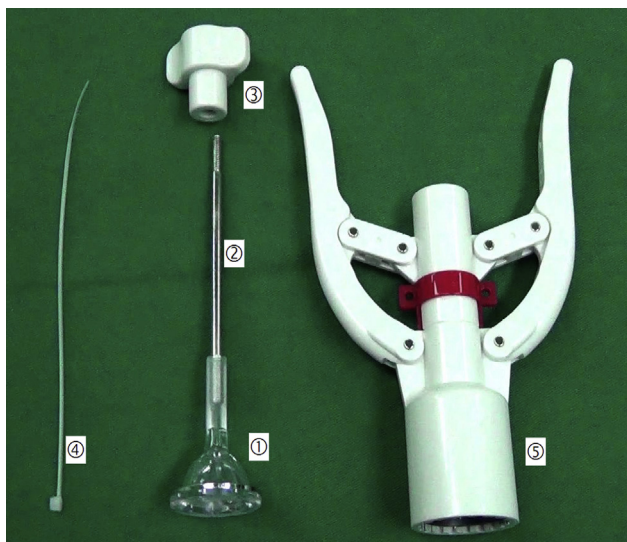
The stenotic dorsal preputial ring was longitudinally incised or bluntly dissected by mosquito forceps to prepare for the placement of the glans bell. Lengthening and plasty were performed for ankylosis of the preputial frenulum if it was too short. A glans bell of proper size was then placed to cover the corona (fig. 3, a). The dorsal and lateral foreskins were pulled over the bell with 4 mosquito forceps and fixed around the groove of the glans bell with strapping tape (fig. 3, b). The handler was placed on the



**Figure 1.** CCSAC design includes glans bell (1), cartridge (2), tube (3), safety (4), trigger (5), circular scalpel (6) and stapler (7).

### Patient indications for CCSAC

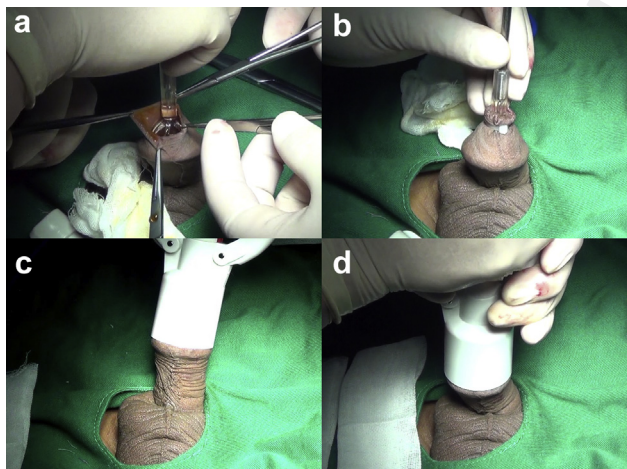
Indication	No. Pts (%)	CCSAC Exclusion (No. pts)
Long prepuce	38 (61.3)	—
Recurrent balanoposthitis	12 (16.1)	Uncontrolled diabetes (2)
Phimosis:		
Congenital	16 (19.4)	Micropenis (4), hypospadias (2)
Acquired	3 (3.2)	Peyronie disease (1)



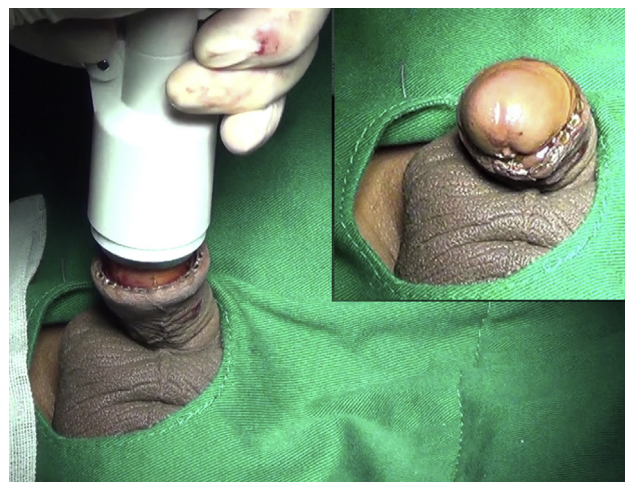**Figure 2.** CCSAC consists of glans bell (1) with column (2) and wing nut (3), strapping tape (4) and handler (5).

glans bell along its column and secured by a wing nut (fig. 3, c). The safety lock on the handler was removed. The operator squeezed and held the handles for 20 seconds (fig. 3, d), which triggered the internal circular scalpel blade and stapler for foreskin removal and incision site anastomosis. A total of 18 stainless steel staples were applied along the incision edges. The handler was unclamped and separated from the penis after removing the wing nut (fig. 4).

The incision site was bandaged with a gauze strip. Direct pressure was applied by the operator for 5 minutes



**Figure 3.** Circumcision using CSSAC. *a*, ostium preputiale is pulled open with 4 mosquito forceps to expose glans. *b*, glans bell is placed over glans corona and wrapped by prepuce. Distal prepuce is secured to glans bell column with strapping tape. *c*, CCSAC handler is placed along glans bell column and secured by wing nut. Prepuce is squeezed between handler and anvil of glans bell. *d*, operator triggers circular scalpel and stapler by squeezing and holding handles for 20 seconds.



**Figure 4.** CCSAC handler unclamped and separated from penis. Inset, extemporaneous penile appearance after circumcision.

to achieve hemostasis. Any residual skin gap or bleeding area that was not covered by staples was closed by simple interrupted sutures using 5-zero polyglactin. Procedure time began at the application of the first mosquito forceps to the foreskin and ended immediately before bandage application.

Patients were monitored for 2 hours postoperatively before being released and were allowed to drive home alone. They were asked to return to our clinic on day 3 postoperatively for a bandage change and instructed to remove the bandage at home on day 7. They were allowed to bathe after the bandage was removed and have intercourse 4 weeks postoperatively.

Patients were followed at day 3, and weeks 1, 2, 4 and 12 after the procedure. Complications and outcomes were assessed. Patients were given a satisfaction survey requesting comments on post-procedural penile cosmesis, discomfort and the likelihood of recommending the procedure (see Appendix).

## RESULTS

A total of 39 underwent circumcision using size D26 CCSAC and in 23 size D30 was used. Mean  $\pm$  SD procedure time was  $7.7 \pm 2.6$  minutes. Patients were comfortable wearing regular undergarments and returned to full physical activity after a 3-day healing period postoperatively. As expected, 7 days postoperatively the staples began to fall out of the incision site. All staples usually fell out within 2 weeks (mean  $10.4 \pm 1.6$  days).

No major complications were observed in our study. One minor complication was a delay in staples falling out in 2 patients. In these cases the remaining staples were manually removed with mosquito forceps on day 14. Another minor complication developed in 1 patient with intraoperative bleeding at the preputial frenulum ankylosis site.

The wound was immediately cleaned and sutured. This isolated case was due to a delay in bandaging and direct pressure to the incision site by an inexperienced provider in training. No other complications related to staples were reported.

The overall complication rate was 4.8% (3 of 62 cases). No infection or excessive foreskin excision was noted. No edema was seen at the penis 7 days postoperatively. There was no complaint of painful intercourse or difficult erection 4 weeks after the procedure.

No pain was reported during the procedure. The average pain level during recovery was 3 on a scale of 0—no pain to 10—the worst pain. Thus, no prescription pain medication was needed postoperatively.

All patients were satisfied with penile cosmesis after circumcision (fig. 5). They would recommend the use of this device to a friend.

## DISCUSSION

Our results demonstrate that CCSAC offers clinical benefits as a novel circumcision device. It allows for a short procedural time of about 8 minutes compared to the average of 20 to 40 minutes required by WHO recommended methods.<sup>9</sup> It also provides an excellent cosmetic result. The cicatrice created due to the circular cutter and staple anastomosis is smooth instead of the more nodular appearance commonly seen with the traditional suturing method. CCSAC produces a softer incision area with less postoperative pain using staple anastomosis compared to

other devices that use a rigid ring as a clamp at the surgical site, which causes compression and hyperemia postoperatively and, thus, patient discomfort and pain. CCSAC has a minimal healing period of about 3 days compared to other devices, such as the Shang ring and Alisklamp, which usually require 7 days before the ring is removed and another 1 to 2 weeks for the wound to heal.

However, a disadvantage of CCSAC is residual hemostasis control since it is achieved mainly by applying direct pressure by the operator. Another limitation is the requirement for multiple sizes of glans bells for glans of different sizes. Also, CCSAC is contraindicated in patients with a thick foreskin due to the limited stapling power of the small staples and in patients with a prepuce not long enough for device use.

The main limitation of our study is that only adults were enrolled for the procedure. We plan to further investigate its application in the pediatric population. Furthermore, larger, prospective studies are needed to ascertain outcome reproducibility since only 62 patients were enrolled in this pilot study. The complication rate of 4.8% (3 of 62 patients) could have been improved by enrolling a larger patient sample and excluding complications due to by operator inexperience.

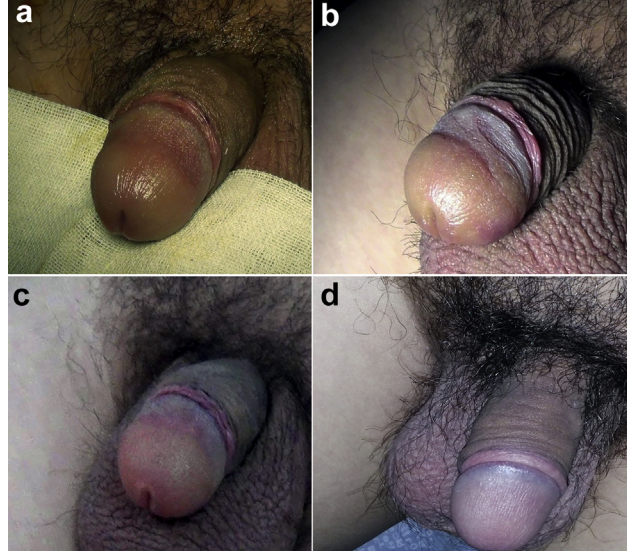
## CONCLUSIONS

CCSAC is a simple, operator friendly circumcision device that offers excellent performance, including short procedural time, fast recovery and a short postoperative edema period along with appealing cosmesis. It was also designed to be economical since the device is disposable and circumcision can be easily performed using local anesthesia on an outpatient basis. No major complications were found in our study. As such, to date there have been minimal drawbacks to this technique.

## APPENDIX

### Patient survey after circumcision using CCSAC

Survey Questions	Patient Answers
1. How would you rate the pain level during recovery?	Please give a score from 0 to 10 with 0 being the least pain and 10 being the most pain.
2. How would you rate the discomfort level of the surgical site during recovery?	Comfortable Okay for a surgical procedure Very uncomfortable
3. Are you satisfied with the cosmetic appearance of the penis after the circumcision?	A. Satisfied B. Neutral C. Not satisfied
4. Overall, are you satisfied with the outcome of the procedure?	A. Satisfied B. Neutral C. Not satisfied
5. Would you recommend this procedure to a friend in need?	A. Yes B. Not sure C. No



**Figure 5.** Penile appearance after circumcision. *a*, day 1. *b*, day 3. *c*, day 7. *d*, day 14.

## REFERENCES

- Bhattacharjee PK: Male circumcision: an overview. *Afr J Paediatr Surg* 2008; **5**: 32.
- Tobian AAR, Gray RH and Quinn TC: Male circumcision for the prevention of acquisition and transmission of sexually transmitted infections: the case for neonatal circumcision. *Arch Pediatr Adolesc Med* 2010; **164**: 78.
- Larke NL, Thomas SL, dos Santos Silva I et al: Male circumcision and penile cancer: a systematic review and meta-analysis. *Cancer Causes Control* 2011; **22**: 1097.
- Morris J and Wamai RG: Biological basis for the protective effect conferred by male circumcision against HIV infection. *Int J STD AIDS* 2012; **23**: 153.
- Krill AJ, Palmer LS and Palmer JS: Complications of circumcision. *Sci World J* 2011; **11**: 2458.
- Mokal N and Chavan N: Modified safe technique for circumcision. *Indian J Plast Surg* 2008; **41**: 47.
- Horowitz M and Gershbein AB: Gomco circumcision: when is it safe? *J Pediatr Surg* 2001; **36**: 1047.
- Mousavi SA and Mohammadjafari H: Circumcision with the Plastibell device in hooded prepuce or glanular hypospadias. *Adv Urol* 2009; **2009**: 864816.
- Musau P, Demirelli M, Muraguri N et al: The safety profile and acceptability of a disposable male circumcision device in Kenyan men undergoing voluntary medical male circumcision. *Urol J* 2012; **9**: 700.
- Decastro B, Gurski J and Peterson A: Adult template circumcision: a prospective, randomized, patient-blinded, comparative study evaluating the safety and efficacy of a novel circumcision device. *Urology* 2010; **76**: 810.
- Hategekimana T, Bitega JP, Ngeruka ML et al: 598 National safety and efficacy study of PrePex, a new device facilitating non-surgical, bloodless circumcision with no anesthesia and no sutures, for resource limited settings. *J Urol, suppl.*, 2011; **185**: e241, abstract 598.
- Wu X, Wang Y, Zheng J et al: A report of 918 cases of circumcision with the Shang Ring: comparison between children and adults. *Urology* 2013; **81**: 1058.
- Bode CO, Ikhisemogie S and Ademuyiwa AO: Penile injuries from proximal migration of the Plastibell circumcision ring. *J Pediatr Urol* 2010; **6**: 23.
- Weiss HA, Larke N, Halperin D et al: Complications of circumcision in male neonates, infants and children: a systematic review. *BMC Urol* 2010; **10**: 2.
- Pieretti RV, Goldstein AM and Pieretti-Vanmarcke R: Late complications of newborn circumcision: a common and avoidable problem. *Pediatr Surg Int* 2010; **26**: 515.
- Ravitch MM and Steichen FM: A stapling instrument for end-to-end inverting anastomosis. *gastrointestinal tract. Ann Surg* 1979; **189**: 791.

## EDITORIAL COMMENT

The CCSAC is a novel circumcision device based on bowel anastomotic stapler principles. It has the potential for widespread use, particularly considering the recent WHO recommendation that "male circumcision should be considered an efficacious intervention for HIV prevention in countries and regions with heterosexual epidemics, high HIV and low male circumcision prevalence."<sup>1</sup>

The CCSAC is unique in that it can be performed on an outpatient basis and no external device remains on the patient. Its most substantial hindrance for widespread use will be cost (\$200 per nonreusable device). For reference the cost of 1

dorsal slit circumcision is \$17.67 and using the Shang Ring costs \$18.91.<sup>2</sup> Just as some bowel anastomosis staplers are reusable, perhaps a reusable version of the CCSAC could be developed. This would greatly advance its utility for mass circumcision efforts and also for the growing need for cost-effective health care in developed countries.

**Mary K. Samplaski**

*Division of Urology  
Department of Surgery  
Mount Sinai Hospital  
University of Toronto  
Toronto, Ontario, Canada*

## REFERENCES

- WHO: HIV/AIDS: Male Circumcision for HIV Prevention. Available at <http://www.who.int/hiv/topics/malecircumcision/en/>. Accessed December 11, 2013.
- Bratt JH and Zyambo Z: Comparing direct costs of facility-based Shang Ring provision versus a standard surgical technique for voluntary medical male circumcision in Zambia. *J Acquir Immune Defic Syndr* 2013; **63**: e109.